
	SRI DEVARAJ URS COLLEGE OF NURSING, TAMAKA, KOLAR Remedial Class Time Table	Format No.	ACD-09
		Issue No.	02
	Rev. No.	00	
	Date:	01-09-08	

2.3.5 The Teaching Learning process of the institution nurtures creativity skills and innovation among students by using **LCD, FLANNEL BOARD, CHARTS, MODEL, OHP, EDUCATIONAL CHARTS AND VIDEO & SIMULATION** etc., for the academic year 2023-2024

1. LCD



2. MODEL



Gayathri
IQAC

Sri Devaraj Urs College of Nursing
Tamaka, Kolar-563101.

[Signature]

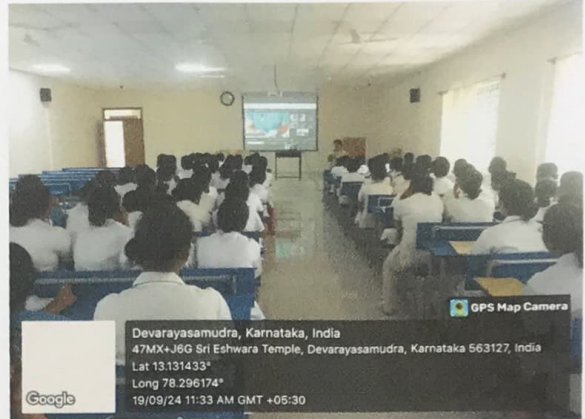
Principal
Sri Devaraj Urs College of Nursing
Tamaka, Kolar-563103



**SRI DEVARAJ URS COLLEGE OF
NURSING, TAMAKA, KOLAR**
Remedial Class Time Table

Format No.	ACD-09
Issue No.	02
Rev. No.	00
Date:	01-09-08

3. VIDEO



4. SIMMULATION




5. CHARTS



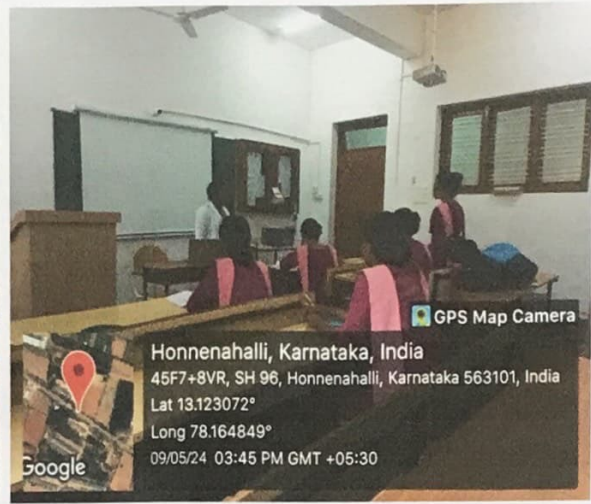
Gayathri
IQAC

Sri Devaraj Urs College of Nursing
Tamaka, Kolar-563101.


Principal
Sri Devaraj Urs College of Nursing
Tamaka, Kolar-563103

	SRI DEVARAJ URS COLLEGE OF NURSING, TAMAKA, KOLAR Remedial Class Time Table	Format No.	ACD-09
		Issue No.	02
	Rev. No.	00	
	Date:	01-09-08	

6. OHP



7. Research dissertation



Gayathri

IQAC

Sri Devaraj Urs College of Nursing
 Tamaka, Kolar-563101.

[Signature]

Principal


Sri Devaraj Urs College of Nursing



**SRI DEVARAJ URS COLLEGE OF
NURSING, TAMAKA, KOLAR**
Remedial Class Time Table

Format No.	ACD-09
Issue No.	02
Rev. No.	00
Date:	01-09-08

8. Journal Club Presentation



Gayathri

IQAC
Sri Devaraj Urs College of Nursing
Tamaka, Kolar-563101.

Principal
Sri Devaraj Urs College of Nursing
Tamaka, Kolar-563103

SRI DEVARAJ URS COLLEGE OF NURSING,TAMAKA,KOLAR.

MIDWIFERY AND OBSTETRICAL NURSING

OBJECTIVE STRUCTURED CLINICAL EXAMINATION(OSCE)

STATION: 01

Case Scenario :01

History of Present Illness: A pregnant 20-year-old women at 32 weeks of gestation came with the complaints of headache and blurring of vision.

Past Medical History: Pregnancy progressing normally to this point

Physical Exam: On examination, blurring of vision and pedal edema present.

Her **BP** was 150/90 mmHg.

Fetal USG done, consistent with dates and within normal limits

- 1) List five signs and symptoms of early recognition of pre-eclampsia .
- 2) write 5 immediate nursing actions taken for eclampsia patient.

Case Scenario: 02

History of present Illness: 24-year-old G₁P₀ L₀A₀Female presents with complaints of severe Nausea with Vomiting. It has been 2 or 3 months since her LMP.

Past Medical History: Normal.

Physical Exam: A febrile, BP= 120/80, P= 105. Patient is pale, vomiting, and abdomen is non tender.

Investigations: HCG is 95,000 IU/ml. uterine ultrasound revealed a snowstorm pattern and no fetus was detected.

- 1) Write the nursing care for hyperemesis gravidarium patient
- 2) Write health advises gives for hyperemesis gravidarium patient

Case scenario: 03

History of Present Illness: A 27-year-old G₁ pregnant woman at 17 weeks ultrasonography done. She has no complaints.

Past Medical History: As above. Pregnancy progressing normally to this point.

Physical Exam: Physical examination, including vital signs, is normal. Ultrasound reveals three fetuses are present.

- 1) Identify the diagnosis.
- 2) What advices are to be given to the mother?

Case Scenario: 04

History of Present illness: A 25-year-old G₂P₁ with 39 weeks for evaluation. Her diabetes was diagnosed at 25 weeks was initially controlled with diet, but she has required insulin since 32 weeks. Checks blood sugars four times a day.

Past Medical History: Home insulin regimen

Physical Exam: Vital signs are normal; fetal heart tracings are good. Blood sugar is controlled. Fundus measurements appropriate. Urinalysis negative. No edema.

- 1) Identify the diagnosis.
- 2) What advices are to be given to the mother?

Case Scenario: 05

Calculation of EDD

Situation: You had received a Primi mother at OPD for first time for her Antenatal checkup and had confirmed her pregnancy and now calculate her EDD according to her LMP mentioned below.

- 1) Client Name: Mrs. Seema, who is 30 years old, she got her LMP on 10 March ²⁰²⁰. Calculate her EDD.
- 2) List any four positive signs of pregnancy in first trimester.

STATION: 02

Care Plan: 01

Mrs.Latha age 30yrs presents with 8 months of Amenorrhea with Fatigue since 2 months. Previously, the patient was able to do her household work, but for the past 2 months, she gets tired even with minimal work. On walking about 50-60min, Patient Complains of Fatigue, Giddiness, Paleness. On Investigations hb was 8gms/dl and diagnosed with moderate anemia.

- 1) Formulate three nursing diagnosis according to the priority.
- 2) Write two nursing care plan.

Care plan: 02

Mrs.kavitha age 30 yrs, G₂P₀ with 8 months of Amenorrhea presents with generalized edema since 10 days, insidious in onset, initially noticed in the lower limbs which have gradually progressed to involve the upper limbs and face. It is present throughout the day not relieved by overnight rest or by limb elevation in the morning. On Abdominal Inspecting the Abdomen uniformly distended, Flanks not full and Fundal height is 28 cm & Abdominal Circumference is 85 cm and F.H.S is 146/min, regular and diagnosed with mild Pre-Eclampsia.

- 1) Formulate three Nursing Diagnosis according to the priority.*
- 2) Write two Nursing Care Plan.*

Care plan: 03

Mrs. Anita age 23 years with 9 months Amenorrhoea with a history of previous LSCS and was admitted for safe confinement. Patient complaints of Backache since Morning in the lower mid-back, non-radiating and not associated with pain abdomen. No history of leak PV or bleeding PV. Fetal movements are well perceived. Ultrasonography reveals full term single Intrauterine Pregnancy with previous LSCS with longitudinal lie with Cephalic Presentation not in labour.

- 1) Formulate three nursing diagnosis according to the priority.
- 2) Write two nursing care plan.

Care plan: 04

Mrs. Lakshmi age 23 years Primigravida comes with 7 months of amenorrhea with sudden painless moderate bleeding on Obstetrical Examination Fundal height was 27cms, Uterus was soft and relax, FHR 140 b/pm. Ultrasound

reveals Low Lying placenta with no detectable fetal anomalies diagnosed as Placenta Previa.

- 1) Formulate three Nursing Diagnosis according to the priority.
- 2) Write two Nursing Care Plan.

Care plan: 05

Mrs. Vasantha age 26 years Primigravida comes with 8 months of Amenorrhea Abdomen looks small. Mother complains of feeling less fetal movements. On Abdominal Examination fundal height 28cms, Uterus felt full of fetus, FHR 140bpm. Ultrasound reveals single fetus in cephalic presentation, placenta normal, amniotic fluid 4cm and diagnosis suggests of Oligohydramnios

- 1) Formulate three Nursing Diagnosis according to the priority.*
- 2) Write two Nursing Care Plan.*

STATION-III

PROCEDURE-01

Scenario : Client Mrs. Pramialla is a 29-year-old, G₂P₁L₁A₀Sb₀ with previous normal vaginal delivery. She has been healthy in this pregnancy and has no major medical problems overall. She has 2 previous antenatal care visits in this pregnancy without problem. She comes today for another routine visit. You have already collected the history and had found everything normal. Now do antenatal examination 36-weeks of pregnancy.

PROCEDURE-02

Postnatal Assessment

Scenario : A 20 year old primipara gave birth 1 day ago. She had a vaginal delivery with a medio lateral episiotomy. Perform postnatal examination for the mother.

PROCEDURE-03

Breast Examination

Scenario: A 23 year old primipara with LSCS. Baby is in NICU for observation. She is on 3th postnatal day.

Perform breast examination to check any abnormality.

PROCEDURE-04

Scenario : A full term newborn baby is just born. The baby is crying and looks pink. Demonstrate the

immediate essential care you will provide for the baby.

STATION:3 (5)

Scenario: Multipara women delivered to male baby and is on delivery table. Delivered placenta immediately after delivery of baby. Now do placental examination to find out any abnormality.